

Malaria Parasites of the "Borriguero" Lizard, *Ameiva ameiva*
(Sauria: Teiidae) in Panama

SAM R. TELFORD, JR.

Malaria Parasites of the "Borrigerro" Lizard, *Ameiva ameiva* (Sauria: Teiidae) in Panama*

SAM R. TELFORD, JR.†

The Florida State Museum and Department of Zoology, University of Florida,
Gainesville, Florida 32601

SYNOPSIS. The teiid lizard *Ameiva ameiva praesignis* in Panama is parasitized by 2 species of *Plasmodium*: *P. cnemidophori* Carini and *P. diminutivum* sp. n. The Panamanian strain of *P. cnemidophori* has thick macrogametocytes which are larger than the oval microgametocytes, and schizonts which contain 42-119 nuclei. *P. diminutivum* is characterized by round to oval gametocytes which are usually smaller than the host cell nucleus; fan-shaped schizonts with 4-6 nuclei; and prominently vacuolated young stages, with a thick band of chromatin along the periphery of the vacuole.

Index Key Words: *Plasmodium cnemidophori*; *Plasmodium diminutivum* sp. n.; lizard, *Ameiva ameiva*; structure; taxonomy; light microscopy.

THE "borriggerro" lizard, *Ameiva ameiva praesignis* (Baird & Girard), forms a conspicuous component of the rich saurian fauna in Panama. In contrast to the other host species involved in my continuing studies of the neotropical saurian malarial (8-11), this lizard is an inhabitant of savannah or low secondary forest where it occupies distinct, fairly small home ranges centered around burrows in which it passes the night. It is truly a "dooryard" species, well adapted to human surroundings, and is thought to have extended its range from South America northward into Panama, where it is distributed discontinuously, perhaps as a consequence of human alteration of the forest (3).

Examination of 79 *A. a. praesignis* from several localities in Central Panama revealed the presence of 2 malaria parasites. One of them, which produces very large schizonts and gametocytes, I consider to be *Plasmodium cnemidophori*. The 2nd, a tiny saurian malaria, apparently is a new species.

MATERIALS AND METHODS

Ameiva ameiva praesignis were collected alive in the field by mammal traps or by noosing, and brought to Gorgas Memorial Laboratory in Panama City for examination. Thin blood smears obtained by clipping toes, were fixed in absolute methanol and stained by the Giemsa's method at pH 6.8 for 1 to 1.5 hr. Slides were screened at 400 \times and parasites examined and measured by calibrated ocular micrometer at 1000 \times . All measurements are expressed in micrometers. Statistical comparison of the means was done by the *t*-test.

The description of *P. cnemidophori* is based upon several slides from a single acute though low level infection, that of the new species on three acute stage infections.

* This investigation was supported by Gorgas Memorial Laboratory, Panama, by Biomedical Sciences Support Grant RR-07021, from the U.S. Public Health Service (to the University of Florida), and by the Florida State Museum.

† Messrs. Henry Van Horn and Norberto Guerrero, Gorgas Memorial Laboratory, were particularly helpful in collecting the lizards used in this study.

RESULTS

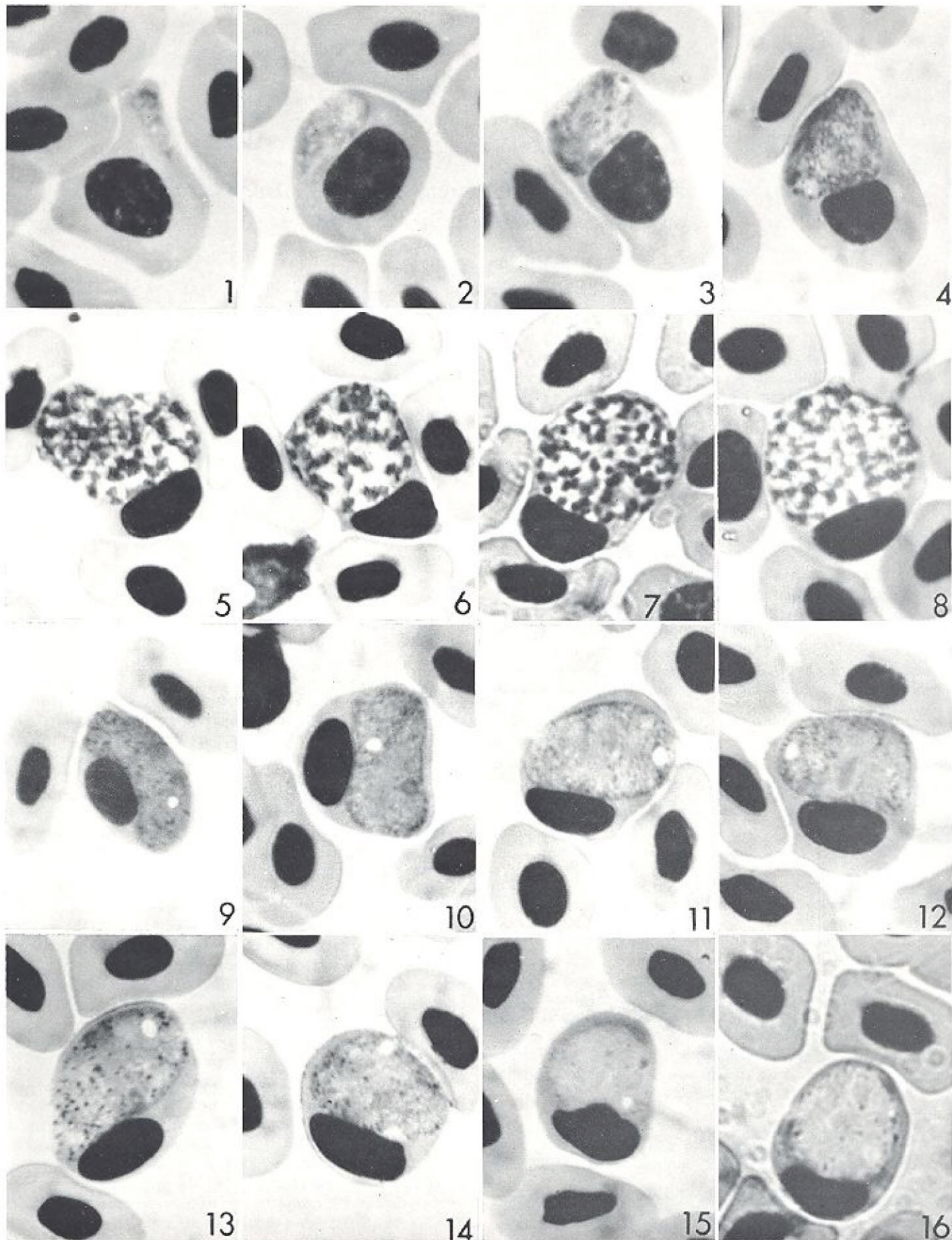
Plasmodium cnemidophori Carini, 1941

DESCRIPTIVE ACCOUNT

Trophozoites.—The smallest stage seen was 1.5×1.5 , in an erythroblast. The nucleus was almost square and about twice the size of the scanty cytoplasm. There was neither vacuole nor pigment in this stage. Trophozoites 2×2 were roughly triangular, with the grayish cytoplasm approximately equal in size to the deep red-staining nucleus. No vacuoles were evident, but minute dots of dark pigment could be detected. Uninucleate parasites which attained sizes of $4-8 \times 2-3$ and lacked vacuoles (Fig. 1) apparently were destined to become schizonts. They were oval to almost triangular and prominently pigmented. No cytoplasmic processes were observed at any stage of development.

Schizonts.—Once it began, nuclear division apparently occurred very rapidly. No binucleate schizonts were observed. Tetranucleate forms (Fig. 2) were $6-9 \times 3-5$; after the next nuclear division, schizonts containing 8 nuclei were $9-11 \times 4-6$. From this point on divisions might become irregular, and odd numbers of nuclei might be seen in schizonts (Figs. 3, 4). As the numbers increased, the schizonts became rounded, with the largest oval to nearly round. Pigment granules aggregated into irregular large masses in the younger schizonts; these often appeared as squarish blocks of dark golden pigment in the most mature schizonts. No vacuoles were seen in schizonts. Apparently mature schizonts (Figs. 5-8) were 13.0 ± 0.4 (10-15) \times 10.8 ± 3 (8-13) and contained 66.0 ± 3.3 (42-119) nuclei ($n = 25$).

Gametocytes.—The smallest stages containing vacuoles and interpreted to be gametocytes were elongate and spindle-shaped, measured 6×2 , and contained pigment. By the time gametocytes reached a length of 10×4 , the pigment granules had aggregated to form a large golden mass at one end of the parasite. In mature gametocytes (Figs. 9-16) the granules were dispersed as dark dots in the cytoplasm. Mature macrogametocytes (Figs. 9-14) were 16.0 ± 0.5 (13-20) \times 8.9 ± 0.3 (6-12) ($n = 20$).



The nucleus could be detected as a broad red-stained band across the parasite; a round, red-staining nucleolus usually was apparent. Mature microgametocytes (Figs. 15, 16) were 11.8 ± 0.9 (10-15) \times 8.8 ± 0.6 (7-10) ($n = 5$). Nuclear material was dispersed within the cytoplasm. Despite the difference in sample size, the difference in mean gametocyte length between sexes was highly significant ($P < 0.01$). All gametocytes seen had at least 1 vacuole, and 2 vacuoles were observed in each of 2 gametocytes.

Exoerythrocytic stages.—No exoerythrocytic forms clearly belonging to *P. cnemidophori* were observed either in circulating or in fixed cells of various tissues.

Types of host cells parasitized.—Uninucleate parasites were found in proerythrocytes, with 2 exceptions. One was seen in an erythroblast and another, with a vacuole, in an erythrocyte. Where host cells could be identified, all schizonts seen were in proerythrocytes. All gametocytes, immature and mature, parasitized erythrocytes.

Effects upon host cells.—In every case schizonts and gametocytes caused hypertrophy and distortion of host cell and nucleus, as well as displacement of the nucleus. Some effect was evident in cells infected by all but the smallest trophozoites. Much of the distortion was due to a predilection of the parasite to assume a position lateral to the nucleus in every instance.

Incidence and levels of parasitemia.—*P. cnemidophori* was found in 4% of the 79 *Ameiva* examined. All parasitemias were less than 1%, and it is probable that the actual incidence of infection was higher than indicated on the basis of single smears. The infection used for this description was followed for 93 days in the laboratory. Parasites were detected only for the first 56 days; thereafter even gametocytes could not be located.

Type host.—*Cnemidophorus lemniscatus lemniscatus* (Linnaeus). Goias State, Brazil (1).

Additional host.—*Ameiva ameiva praesignis* (Baird & Girard). Panama Province and Canal Zone, Republic of Panama.

—*Ameiva ameiva ameiva* (Linnaeus), Brazil (5).

Plasmodium diminutivum sp. n.

DESCRIPTIVE ACCOUNT

Trophozoites.—The smallest stages seen were 1×0.8 - 1×1 , elongate to almost square masses of chromatin with no visible cytoplasm. A vacuole appeared when the trophozoite reached 1.5×1.5 ; cytoplasm was barely evident. As trophozoites became larger, they were elongate with a prominent central vacuole bordered by a thin layer of pale gray cytoplasm at one end and a deep red-staining band of chromatin along the opposite side (Fig. 17). Most became roughly oval in shape as they reach 3×2 in size. Pigment could not be detected in trophozoites.

Schizonts.—The chromatin apparently did not divide until the parasite reached at least 4×2 ; it formed a thick red-stained band along one margin of the vacuole (Figs. 18, 19). The 2nd nuclear division evidently occurred immediately after the 1st, for binucleate schizonts seldom were seen, and those observed were 4×2 . As division was completed, 4-6 separate nuclei became visible along the margin of the oval to round schizont. The vacuole then gradually diminished in size and the schizont assumed an elongate fan shape, with a prominent mass of pale grayish yellow pigment forming the handle of the fan. The

vacuole continued to diminish until segmentation occurred, by which time it had usually disappeared. Apparently mature schizonts (Figs. 20-23) were 4.1 ± 0.2 (3-4) \times 3.1 ± 0.1 (3-4) ($n = 50$) and contained 4.2 ± 0.1 (4-6) ($n = 50$) nuclei. Means of individual infections were 4.2 ± 0.1 and 4.3 ± 0.1 ($n = 25$ in each). Occasional schizonts that appeared mature had 2 (Fig. 20) or 3 (Fig. 21) nuclei; these were excluded from the sample measured as in each case it was not certain that division had ceased.

Gametocytes.—Sexual forms were very rare in the infections studied—only 16 apparently mature gametocytes were found. Immature gametocytes were elongate (Fig. 24), did not stain differentially with regard to sex, and had the pigment confined to a single, large mass. Mature gametocytes (Figs. 25-32), which gave the characteristic staining reactions by sex, were round to oval, measuring 5.6 ± 0.2 (5-7) \times 4.8 ± 0.2 (4-6) ($n = 16$). In these there usually was an aggregation of pigment granules into a single larger mass, grayish gold in color, accompanied by several darker individual granules scattered throughout the cytoplasm. Vacuoles seldom were seen in gametocytes, and there was no apparent difference between sexes other than a centralization of nuclear material in macrogametocytes and its apparent dispersal in microgametocytes.

Exoerythrocytic stages.—No parasites were seen in fixed cells of liver, lung, spleen, brain, and heart sections in the most acute infection studied. A single parasitized thrombocyte was noted in another infection, but the parasite may have been *P. cnemidophori*, which also was present.

Types of host cells parasitized.—Trophozoites, schizonts, and gametocytes apparently parasitized only mature erythrocytes.

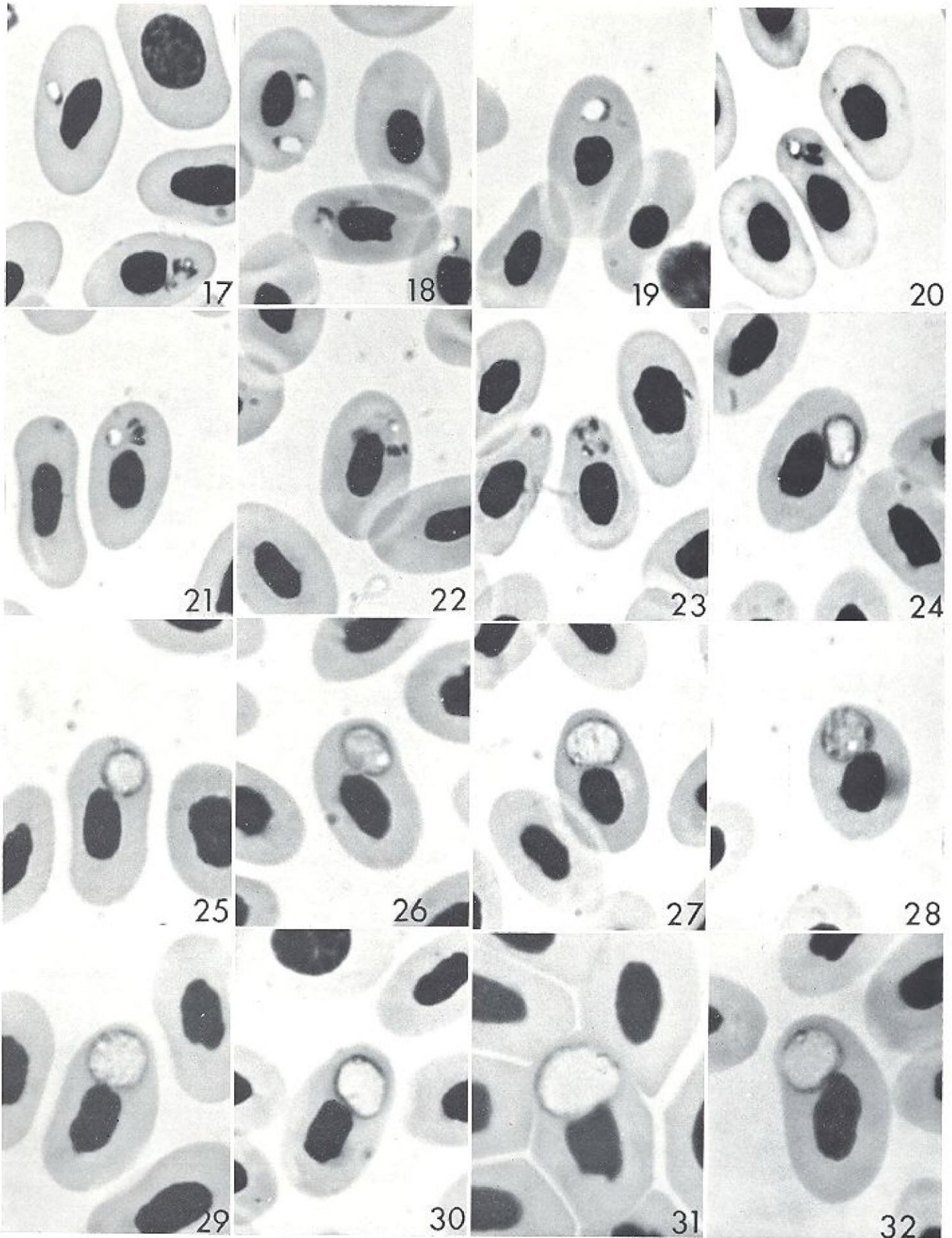
Effects upon host cells.—Trophozoites and schizonts had no apparent effect upon their host cells. Some gametocytes (30%) caused a slight distortion of the host cell, but had no apparent effect upon the nucleus except to often displace it (50%). Parasites were usually polar or lateropolar in position, seldom lateral. Multiple infections were common but there were rarely more than 3 parasites per host cell.

Incidence and levels of parasitemia.—*Plasmodium diminutivum* was encountered in 23% of the 79 *Ameiva ameiva* examined. Parasitemias were usually low, less than 1%; maximum parasitemia observed was 13.2%. Asexual stages only usually were present.

TAXONOMIC SUMMARY

Plasmodium diminutivum sp. n.

Diagnosis.—(Erythrocytic stages from type host. All measurements in μ m.) Youngest trophozoites very small, 1×0.8 - 1×1 , with chromatin masses and barely visible cytoplasm; larger asexual trophozoites elongate, with prominent central vacuole, become roughly oval as they reach size of 3×2 ; nuclear division not occurring until parasites reach 4×2 ; mature schizonts round or oval, 4.1 ± 0.2 (3-4) \times 3.1 ± 0.1 (3-4), with 4-6 nuclei in fan-like arrangement along margin, with prominent mass of pale yellow-grayish pigment; gametocytes rare (in infections studied); immature gametocytes elongate, not stained differentially with regard to sex, with single mass of pigment; mature gametocytes, staining differentially with regard to sex, round to oval, 5.6 ± 0.2 (5-7) \times 4.8 ± 0.2 (4-6), usually with single, grayish-golden pigment aggregation and several darker granules scattered throughout cytoplasm, usually without vacuoles, with chromatin centralized in macro- and dispersed in microgametocytes.



Type host.—*Ameiva ameiva praesignis* (Baird & Girard) (Sauria, Teiidae). Village of Guayabalito on the Rio Chagres, Colon Province, Republic of Panama (known also from Panama Province and Canal Zone, Republic of Panama). **Syntype and parasynotype preparations** in the Parasitological Collection of the Florida State Museum. Other parasynotype preparations in the Department of Zoology, University of California, Los Angeles and in Prof. P. C. C. Garnham's collection, Imperial College Field Station, Silwood Park, England.

Remarks

Plasmodium diminutivum is similar to *Plasmodium pifanoi* Scorza & Dagert from *Ameiva ameiva ameiva* from southern Venezuela. It differs, however, from the latter species very significantly in the shape of the schizonts and gametocytes. In my opinion these characteristics alone are sufficient for the placement of the species from the Panamanian "borriguero" lizard in a new species.

DISCUSSION

Plasmodium cnemidophori was described by Carini (1) from the teiid lizard *Cnemidophorus lemniscatus lemniscatus* in Goiás State, Brazil. It was next reported from this host by Lainson & Shaw (5) from 2 other Brazilian localities, and from a 2nd host, *Ameiva ameiva ameiva* in both localities. Two differences are apparent immediately between the descriptions of the Brazilian populations and that of the Panamanian parasite. Trophozoites of the Brazilian strain produce fine pseudopodia, not seen in the Panamanian strain. The greatest difference is in gametocyte size and shape. Carini described macrogametocytes as 12×4.5 and microgametocytes as 9×4 , while Lainson & Shaw stated that the macrogametocyte was 5.0×6.0 , slightly larger than the microgametocyte. This is probably a printing error: their illustrations of gametocytes suggest a size of $\approx 16 \times 7$. The gametocytes of *P. cnemidophori* were described as "banana-shaped" (1, 4, 5). Gametocytes of the Panamanian parasite certainly are not "banana-shaped," although they are usually elongate. Most macrogametocytes are somewhat bulky (Figs. 10-14) and microgametocytes are almost egg-shaped (Figs. 15, 16). Gametocyte shape appears to be one of the least variable taxonomic characters among most of the malarial parasites in Panamanian saurians, and to admit significant geographic variation in this character is disturbing. But it would be less satisfactory to give taxonomic distinction at the species level to this parasite solely because it has thicker gametocytes.

Much the same argument is applicable to the distinction of *P. diminutivum* from *P. pifanoi* Scorza & Dagert (7) from *Ameiva ameiva ameiva* of southern Venezuela. It was characterized by having elongate gametocytes, $15-17 \times 6-8$, and rounded schizonts with 6-12 merozoites, which surrounded a central mass of pigment (i.e., a rosette). A prominent vacuole was present in both asexual and sexual stages.

If round gametocytes were the sole distinguishing character of *P. diminutivum*, then it would best be considered a geographic variant of *P. pifanoi*. This, however, is not the case—*P. diminutivum* schizonts (Figs. 20-23) are fan-shaped at maturity rather than in the form of rosettes, and they contain 4-6 nuclei in contrast to 6-12 in *P. pifanoi*. Vacuoles are consistently present only in the asexual stages of *P. diminutivum*, and the localization of

chromatin as a band along the periphery of the vacuole (Figs. 18, 19) is another distinction.

The other 2 small New World malarial parasites with which *P. diminutivum* should be compared are *Plasmodium minasense* Carini & Rudolph, 1912 and *Plasmodium rhadinurum* Thompson & Huff, 1944. The prominence of the vacuole in *P. diminutivum* distinguishes asexual stages readily from those of both of the latter species, and is as diagnostic of *P. diminutivum* as are the very obvious cytoplasmic projections in the asexual stages of *P. rhadinurum*. *Plasmodium minasense* and *P. rhadinurum* schizonts often have the nuclei arranged in cruciform manner; this has not been observed in *P. diminutivum* infections. The fan-shaped schizonts of *P. diminutivum* appear to be somewhat more elongate than the similarly shaped schizonts of *P. minasense*. Identification of gametocytes could pose a significant problem if host species were unknown. The gametocytes of *P. rhadinurum* and *P. minasense* (in iguanids) often are larger than the host cell nucleus or about equal it in size. Gametocytes of *P. diminutivum*, on the other hand, usually are smaller than the host cell nucleus. *P. minasense* has been reported from skinks only in its original description by Carini & Rudolph (2). Gametocytes were described as 4-5 in diameter, comparable to those of *P. diminutivum*, but the fan-shaped schizont illustrated by these workers was wider and shorter than that of the *Ameiva* parasite, while no description was given of similarities in younger asexual stages.

With this report, *P. cnemidophori* becomes the 3rd saurian malaria known to extend from Brazil into Panama. I have reported earlier (9) the presence of *Plasmodium diploglossi* in Panamanian lizards, and in a recent study Lainson et al. (6) indicated the occurrence of *Plasmodium* (= *Garnia*) *gonatodi*, described originally from Panama (9), in Brazilian lizards.

LITERATURE CITED

1. Carini, A. 1941. Sobre um plasmodio endoglobular e uma Eimeria do lagarto *Cnemidophorus lemniscatus lemniscatus*. *Arch. Biol. S. Paulo* **25**, 205-8.
2. ——— & Rudolph, M. 1912. Sur quelques hématozoaires de lézards au Brésil. *Bull. Soc. Path. Exot.* **5**, 592-5.
3. Echternach, A. C. 1971. Middle American lizards of the genus *Ameiva* (Teiidae) with emphasis on geographic variation. *Univ. Kansas Mus. Nat. Hist. Misc. Publ.* **55**, 1-86.
4. Garnham, P. C. C. 1966. *Malaria Parasites and Other Haemosporidia*. Blackwell, Oxford.
5. Lainson, R., & Shaw, J. J. 1969. New host records for *Plasmodium diploglossi*, *P. tropiduri* Aragão and Neiva, 1909, and *P. cnemidophori* Carini, 1941. *Parasitology* **59**, 163-70.
6. ———, Landau, I., & Shaw, J. J. 1971. On a new family of non-pigmented parasites in the blood of reptiles: Garniidae fam. nov. (Coccidiida: Haemosporidiiida). Some species of the new genus *Garnia*. *Int. J. Parasit.* **1**, 241-50.
7. Scorza, J. V., & Dagert, C. B. 1956. *Plasmodium pifanoi* nov. sp. parasito de *Ameiva ameiva ameiva* de Venezuela. *Noved. Cient. Mus. Hist. Nat. La Salle, Ser. Zool.* **20**, 1-6.
8. Telford, S. R., Jr. 1969. A new saurian malarial parasite, *Plasmodium ballii*, from Panama. *J. Protozool.* **16**, 431-7.
9. ——— 1970. Saurian malarial parasites in eastern Panama. *J. Protozool.* **17**, 566-74.
10. ——— 1971. A malarial parasite *Plasmodium aurulentum* sp. nov. from the Neotropical Forest gecko in Panama. *J. Protozool.* **18**, 308-11.
11. ——— 1972. Malarial parasites of the "Jesu Cristo" lizard, *Basiliscus basiliscus*, in Panama. *J. Protozool.* **19**, 77-81.